

Noninvasive Evaluation of Peripheral Vascular Disease

Norman S. Sorkin, MD

Now most of your patients with a suspected vascular cause for leg pain can be worked up without the additional pain or risks involved with arterial catheterization.

The first signs of arterial insufficiency can be subtle because painful ambulation may be caused by many disorders (such as arthritis, spine disease or muscle disorders). A noninvasive peripheral vascular exam which combines three physiologic tests — dopplers, segmental pressures and pulse volume recordings (PVR) — may give you the information needed to rule out or in vascular cause for your patient's pain (refer to Figures 1 and 2).

The next step in the diagnosis of your patient's vascular disease may be an MRA. Magnetic Resonance Angiography requires only an intravenous injection of Gadolinium (MRI contrast agent). Images of the arteries from the renal arteries to the feet can be made. This imaging can be of the quality that can direct intervention or surgery or medical therapy (refer to Figures 3 and 4).

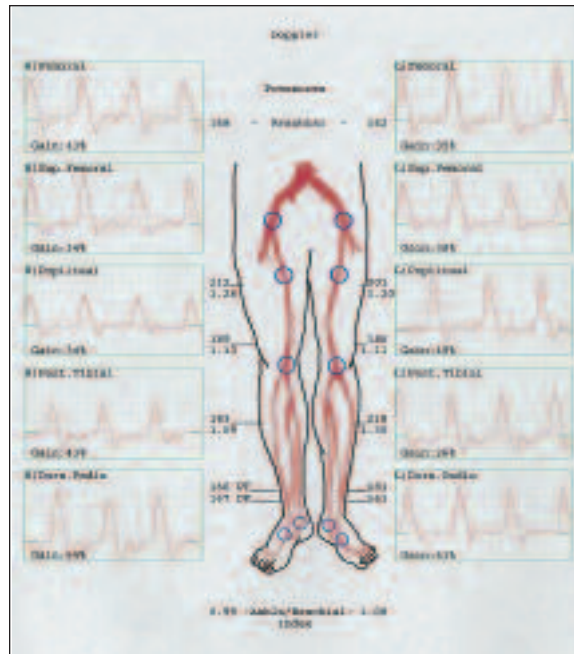


Figure 1: Normal Triphasic Doppler Waveforms.

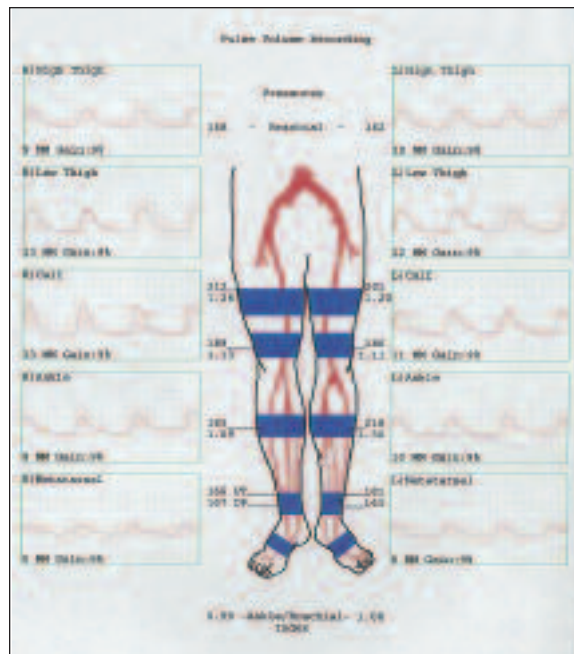


Figure 2: Normal PVRs.

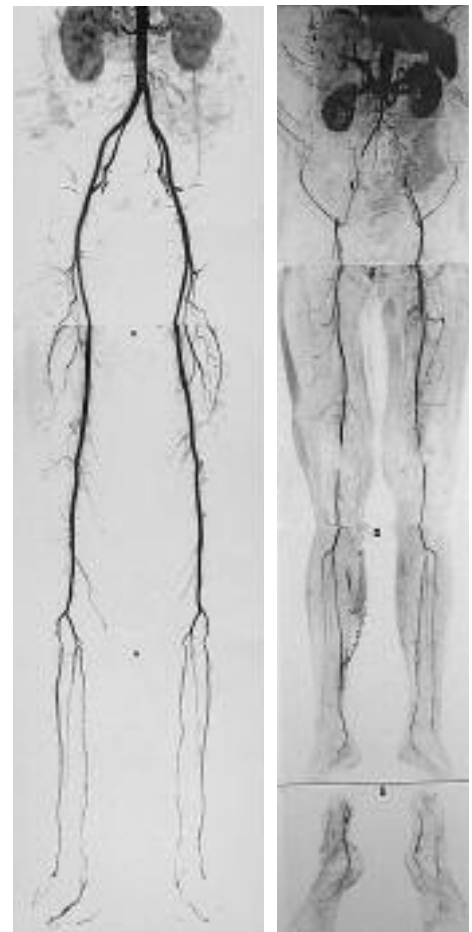

Figure 3: Normal MRA of Abdominal Aorta and Bilateral Lower Extremities.

Figure 4: Example of Multilevel Vascular Disease as depicted by MRA.

Appointments can be scheduled by calling 732-249-4410.

If you have any questions or comments, Dr. Norm Sorkin would be happy to discuss them with you. He can be reached by calling 732-548-2322.